Getty Images

Daniel Fried

Detecting Dental Decay with *Infrared Light*

A variety of optical techniques could overcome some of the shortcomings of more traditional tools for one of the dentist's oldest tasks—finding cavities.

Despite considerable progress in treatment, dental caries—tooth decay—remains the most prevalent chronic disease in both children and adults. Dentists commonly use visual and tactile means (for example, dental probes), coupled with radiography (dental X-rays), to identify caries lesions, or cavities. The widespread use of fluoride has meant that lesions commonly crop up where fluoride doesn't easily penetrate—typically in the pits and fissures of the crowns of posterior teeth (occlusal lesions), or at the contact points in-between teeth (interproximal lesions). That makes them difficult to detect by conventional means. Lesions also congregate near dental root surfaces, and constitute an increasing problem in an aging population.

Fortunately, several new optical imaging devices that use fluorescence and near-infrared (NIR) and shortwave-infrared (SWIR) light have become available to dentists—and dental systems based on optical coherence tomography (OCT) are under development. These techniques not only lack the ionizing radiation required for radiography, but have some other significant advantages over radiographs for detecting and assessing dental caries.

The trouble with X-rays

When dental-caries lesions are identified early via radiography, they can be halted or arrested through partial remineralization with fluoride before surgery is needed. Unfortunately, though, radiographic methods have poor sensitivity for detecting more hidden, occlusal lesions, due to the overlapping topography of the tooth's crown. By the time the lesions become visible to radiography, they have typically progressed deep into the dentin, the inner, calcified tissue that lies

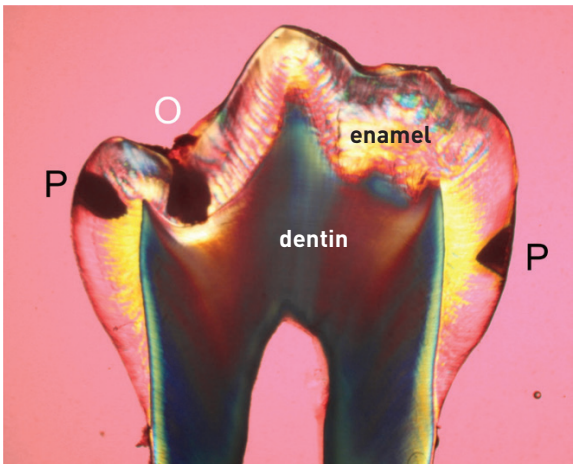

A section of a premolar tooth with interproximal lesions (P) and an occlusal lesion (O), viewed under polarized light with a first-order retardation-I plate. Enamel is more transparent than dentin, and both tissues are birefringent; loss of birefringence due to strong light scattering causes demineralized caries lesion areas (cavities) to appear black.

A dental-caries glossary

Dental caries: The condition commonly known as tooth decay.

Caries lesion: An area in a tooth, commonly called a cavity, that has been demineralized by the activity of oral bacteria.

Interproximal lesion: A cavity situated in areas between adjoining teeth.

Occlusal lesion: A cavity located on the tooth crown (the area where the tooth makes contact with teeth in the other jaw).

Enamel: The hard, mineralized outer surface of a tooth.

Dentin: The hard, porous calcified layer of a tooth that lies beneath the enamel and constitutes the largest portion of the tooth.

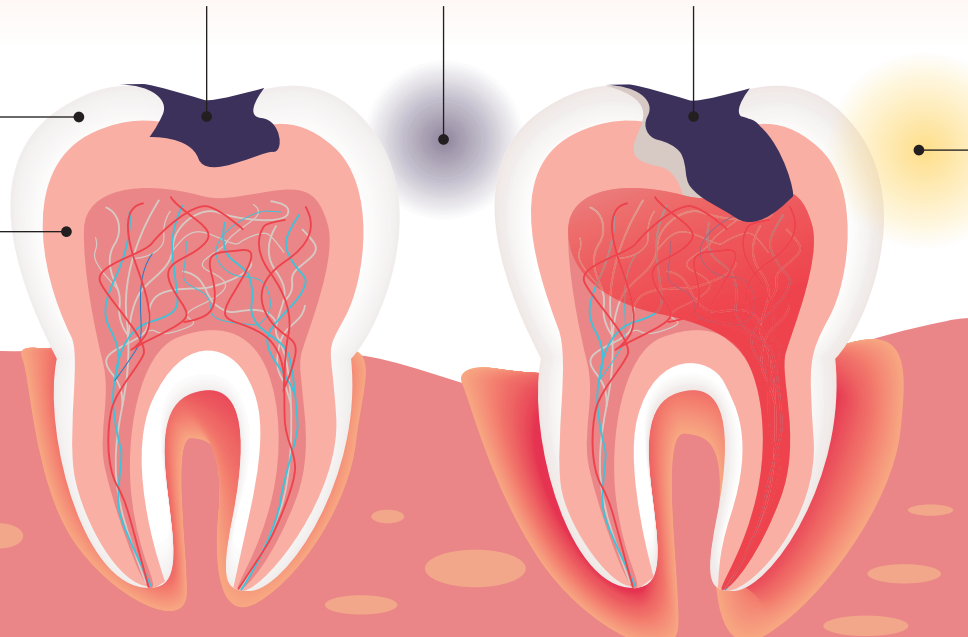

1047-6938/20/05/48/6-$15.00 © OSA

New optical imaging devices that use fluorescence and near- and shortwave-infrared light have become available to dentists, and OCT-based dental systems are under development.

beneath the hard outer layer of tooth enamel. At that point it's too late for nonsurgical intervention to be effective, and the dentist's drill comes out.

Radiography is more sensitive to the interproximal lesions, located between teeth. Even there, however, X-rays typically underestimate the penetration depth of the lesion. New, more sensitive methods are needed to detect these lesions, and to determine whether they are active or have been arrested.

Optical alternatives

Optical methods are not new to characterizing teeth or studying dental caries; polarized-light microscopy, for example, has been used for more than a century. Understanding the potential for new forms of optical imaging in the dental suite, however, requires some background on how caries form.

Oral bacteria, fed by fermentable carbohydrates, produce organic acids that dissolve tooth structure, demineralizing the enamel and dentin. The mineral loss, in turn, leads to pores that create the subsurface lesion areas, and the demineralized tooth structure strongly scatters light. Radiography detects the changes in mineral loss, while optical methods detect changes in light scattering. The acids and bacteria can penetrate deeper into the tooth through the enamel, and spread rapidly through the underlying dentin into the tooth's interior before the decay is visible on a dental X-ray.

If fluoride is present in saliva, lesion areas can be remineralized and arrested by the deposition of fluorapatite, a mineral that fills the pores near the surface of the lesion, forming a highly mineralized, transparent cap. This surface layer, or "scar," over the lesion inhibits its diffusion, arresting further progression. Since the body of the arrested lesion typically remains visible, though, it is difficult for dentists to differentiate between those lesions that are active and progressing and those that are arrested. New optical imaging methods can help dentists to determine if a transparent surface layer has formed over the lesion, and to assess whether the lesion is active.

The first successful optical caries detection devices have employed fluorescence, with several commercial devices already available. Fluorescence-based

Transillumination: The shining of light through an object (such as a tooth) to check for subsurface abnormalities. X-rays are typically used to transilluminate teeth, and lesions are radiolucent due to the lower density of lesion areas.

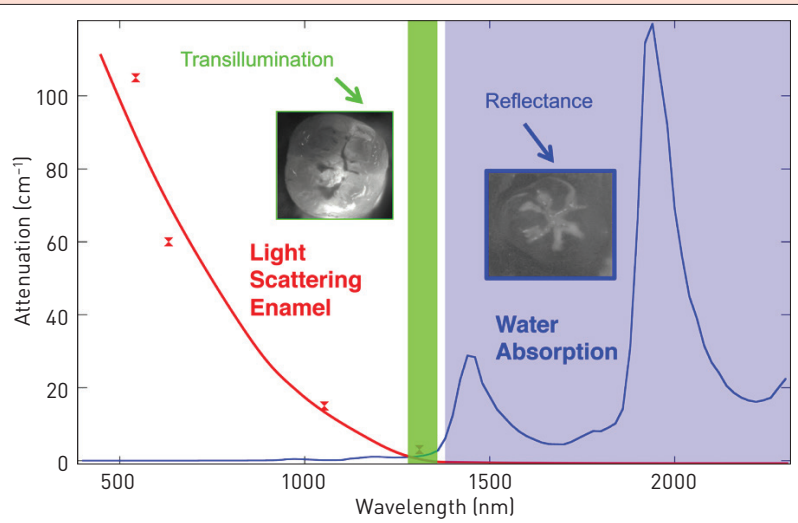

Both light scattering in enamel (red trace) and absorption by water (blue trace) are low at wavelengths near 1300 nm, making those wavelengths best for transillumination. Wavelengths above 1400 nm are best suited for study by reflectance, as scattering in enamel continues to decrease and water absorption does not decrease the contrast between healthy and demineralized tissues.

A.F. Zandona and C. Longbottom, eds., *Detection and Assessment of Dental Caries* (Springer, 2019)

The use of OCT in dentistry was first investigated more than 20 years ago, and many studies have since demonstrated its great potential for imaging dental caries.

IR light roots out decayed areas

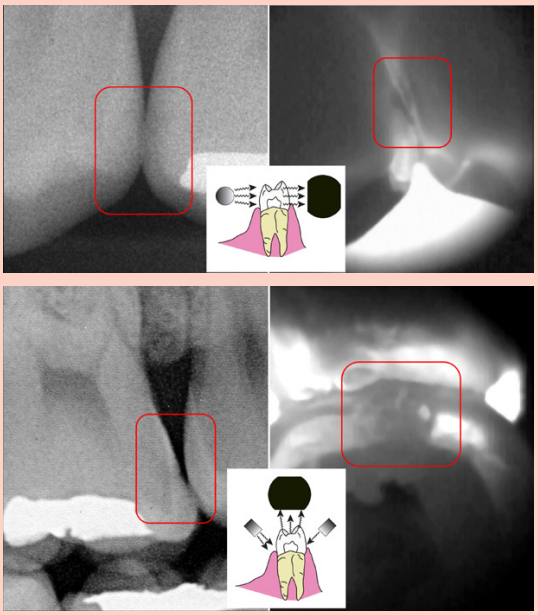

Bitewing X-rays (left) are contrasted with NIR images (right) for proximal transillumination (top row) and occlusal transillumination (bottom row). Because of the high transparency of enamel to NIR light, lesions (red boxes) poorly visible in the radiographs show up with high contrast in the NIR images.

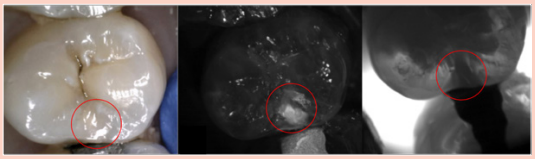

In a tooth that included a stained fissure (color image, left), SWIR cross-polarization reflectance imaging (1500-1750 nm, middle) and occlusal transillumination (1300 nm, right) confirmed an earlier X-ray diagnosis of an interproximal lesion (circled area), but showed that the clinicians' diagnosis of a second lesion in the fissure on the tooth crown was a false positive, attributable to the stain in the fissure.

M. Staninec et al., Lasers Surg. Med. **42**, 292 (2010)
J.C. Simon et al., Lasers Surg. Med. **49**, 215 (2017)

detection devices use one of two approaches. The first relies on the native fluorescence of collagen, present in the dentin that lies beneath the enamel. Lesions on the surface attenuate the collagen's green fluorescence (excited by UV and blue light), making the lesion areas appear darker than the surrounding, sound areas of the tooth.

The other fluorescence approach relies on porphyrins, which originate from hemoglobin and bacteria and which can also become concentrated in the pores of lesions. Porphyrins can be excited by blue to red wavelengths to fluoresce in the red and NIR. The first widely used commercial device exploiting this fluorescence was the Diagnodent from Kavo (Biberach, Germany), developed specifically to detect the "hidden" lesions below the occlusal surface that don't show up on radiographs. The Diagnodent uses longer-wavelength, 655-nm light to achieve greater optical penetration in the tooth.

The long-wavelength advantage

Light scattering in dental enamel is strong at blue wavelengths and decreases by orders of magnitude at NIR and SWIR wavelengths. Enamel is at its most transparent near 1300 nm; therefore, 1300 nm is optimal for transillumination—shining light through the tooth. At longer SWIR wavelengths, water absorption increases, and reflectance imaging for assessing demineralization improves markedly. That's because the increase in water absorption, along with the further decrease in light scattering, reduces the reflectivity from the tooth's sound areas, putting the lesion areas into much higher contrast.

Tooth surfaces are somewhat porous and rapidly accumulate stains, which absorb light strongly and often fluoresce as well. Because dentists use visual examination to identify some cavities, these stained areas can cause false positives—particularly in the pits and fissures of the occlusal surfaces, where most new decay is found and which can't be cleaned effectively. The highly conjugated organic molecules responsible for staining do not absorb light at longer wavelengths, however, and most stains are transparent beyond 1200 nm, in the SWIR. Imaging

at wavelengths beyond 1200 nm is thus advantageous not only because of the higher transparency of enamel, but because the interference from exogenous stains is avoided.

In addition to proximal transillumination—in which light is directed between teeth, in a geometry similar to that of a dentist's bite-wing X-ray—NIR or SWIR light can be directed at the gums at the base of the tooth, with the light transmitted up through the occlusal surface, an approach called occlusal transillumination. Reflectance imaging of the occlusal surface is also valuable for viewing both occlusal and interproximal lesions—and can even pick up false positives in diagnosis attributable to tooth staining.

Clinical studies have shown that NIR imaging can achieve higher diagnostic performance than radiographs, and several NIR imaging systems are available commercially for caries detection. Current commercial systems, however, are only available at wavelengths less than 1000 nm, because of the high cost of sensors at longer wavelengths.

OCT goes dental

The use of OCT in dentistry was first investigated more than 20 years ago, and many studies have since demonstrated its great potential for imaging dental caries. OCT systems commonly operate near 1300 nm, which is convenient for imaging deep into the tooth; the high transparency of enamel at 1300 nm makes optical penetration exceeding 5 mm possible. Thus OCT has the potential to image occlusal and interproximal lesions from the crown of the tooth.

OCT images can show the subsurface spread and penetration of occlusal caries lesions not visible on radiographs, and can also acquire high-resolution images of lesion structure that are valuable not only for assessing the depth and severity of lesions, they can also be used for judging whether lesions are active or arrested. And OCT can be used to monitor lesions to determine if nonsurgical intervention is successful. Further, cross-polarization can be used to increase the contrast of caries lesions in OCT images. An outer, transparent (dark) zone over a bright lesion area in cross-polarized OCT, for example, can clearly show where remineralization treatment has arrested lesion growth.

At present, no clinical dental OCT systems are commercially available. As performance and speed continue to improve and cost decreases, however, systems should soon be available to dentists—opening yet another optical front in the fight against cavities. OPN

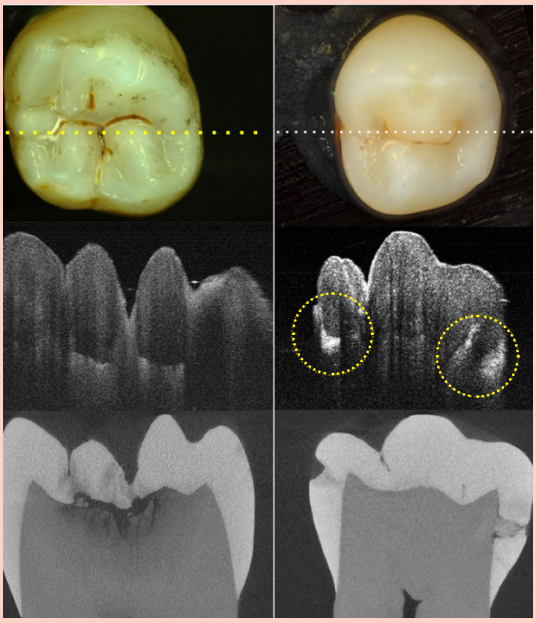

In vitro color, OCT and microCT images of two extracted teeth with occlusal and interproximal lesions. Dotted lines show line of section; lesions are in the yellow circles. OCT images were acquired using a high-speed prototype swept-source OCT system from Axsun Technologies (Billerica, MA), equipped with a MEMS-based scanner capable of acquiring 3D images of an entire tooth.

A.F. Zuluaga et al., Proc. SPIE, v. 10857, Pres. E (2019)

Daniel Fried (Daniel.Fried@ucsf.edu) is with the Department of Preventive and Restorative Dental Sciences, University of California, San Francisco, CA, USA.

References and Resources

- B. Colston et al. "Imaging of hard and soft tissue structure in the oral cavity by optical coherence tomography," Appl. Opt. **37**, 3582 (1998).
- R.S. Jones et al. "Near-IR transillumination at 1310 nm for the imaging of early dental caries," Opt. Express **11**, 2259 (2003).
- M. Staninec et al. "*In vivo* near-IR imaging of approximal dental decay at 1310 nm," Lasers Surg. Med. **42**, 292 (2010).
- O. Fejerskov et al. Dental Caries: *The Disease and Its Clinical Management* (Wiley Blackwell, 2015).
- J.C. Simon et al. "Near-IR and CP-OCT imaging of suspected occlusal caries lesions," Lasers Surg. Med. **49**, 215 (2017).
- A.F. Zandona and C. Longbottom, eds. *Detection and Assessment of Dental Caries* (Springer, 2019).
- A.F. Zuluaga et al. "Real-time visualization of hidden occlusal and approximal lesions with an OCT dental handpiece," Lasers in Dentistry XXV, Proc. SPIE, v. 10857, Presentation E (2019).
- National Inst. of Dental and Craniofacial Research, www.nidcr.nih.gov/research/data-statistics/dental-caries.